

# Wagner SL Revision<sup>®</sup> Hip Stem

Surgical Technique





# Table of Contents

<b>Concept</b> .....	2
<b>Preoperative Planning</b> .....	4
Objective .....	4
X-Ray Image .....	4
Selection of the Implant Length .....	5
Selection of the Implant Diameter.....	5
Effect of the Bone Quality .....	5
Drawing the Preoperative Plan .....	6
Reference Points .....	8
<b>Endofemoral Procedure with Posterior Approach</b> .....	9
Surgical Technique .....	9
<b>Transfemoral Approach</b> .....	14
Surgical Technique .....	15
<b>Postoperative Treatment</b> .....	22

## Concept

Implantation of the Wagner SL Revision Stem requires both extreme care in dealing with the damaged bone and the surrounding tissues and achieving stable implant fixation. It is only under such conditions that good formation of new bone and secure prosthetic fixation can be expected. In young patients it is particularly important to insure that the shortest possible prostheses are implanted. This makes great technical demands on the surgeon. Therefore, the revision prosthesis should only be used by experienced hip surgeons.





## Preoperative Planning

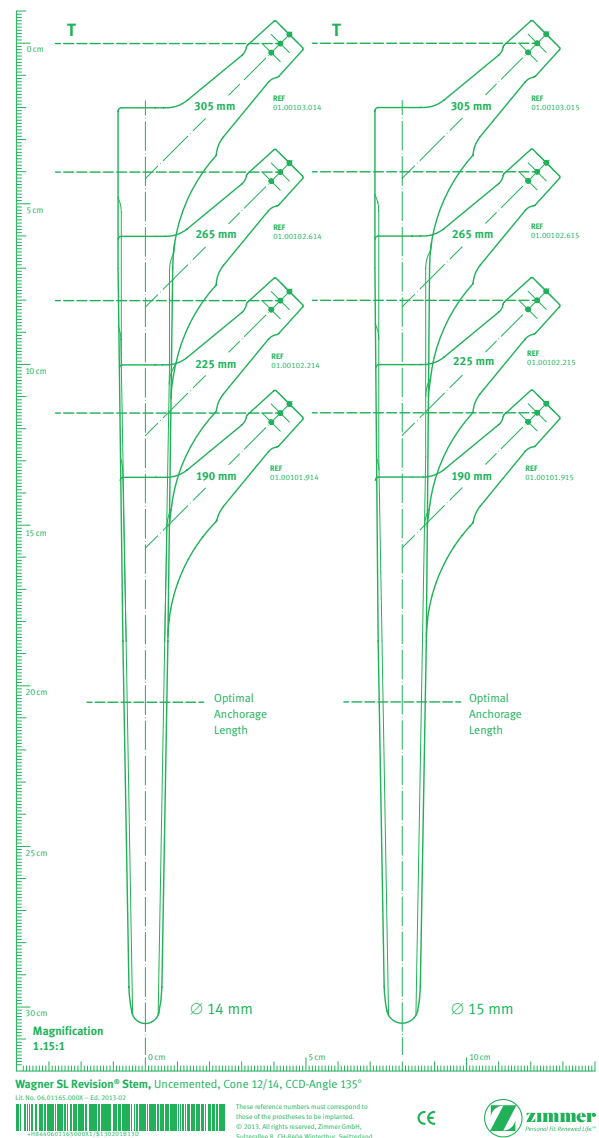
### Objective

One of the most important tasks in preoperative planning is the choice of the correct length of the prosthesis and the necessary stem diameter. Since the depth of penetration of the longitudinal ribs into the bone depends on the strength of the bone, which cannot be estimated with sufficient certainty in the X-ray image, stems of the next larger and smaller diameters should be available during the operation in order to permit the selection of the definitive stem diameter according to the depth of penetration of the conical awl and the fitting trial prosthesis.

In the diagrammatic planning it is possible to compensate for the shortening of the leg resulting from the previous loosening of the prosthesis and to determine the length of a possibly necessary transfemoral approach, taking into account the bone loss in the old prosthetic bed. The decisive advantage of preoperative planning is that the individual steps of the operation and their sequence can be thought out and established in diagrammatic form before the operation. The planned operation can then be performed with confidence. This shortens the time required for the operation and prevents surprises because all the details have been planned and laid down in diagrammatic form. Detailed planning is intended to improve the quality of the surgical intervention.

### X-Ray Image

The basis for the preoperative planning is provided by X-ray images with a defined magnification scale. It has become customary to use the average magnification scale of the standard X-ray technique of 115%. The planning templates are also adjusted to this factor. Digital templates are also available.



Planning templates can be obtained under order nos.:

Art. No.	Ø	Lengths
06.01165.000x	14 mm–25 mm	190 mm, 225 mm, 265 mm and 305 mm

## Selection of the Implant Length

With the planning template that is placed on the X-ray image, the appropriate length of the prosthesis and the desired elongation of the femur can be determined.

The prosthesis should be as short as possible but sufficiently long for the reference line for the center of the head of the prosthesis to touch the tip of the greater trochanter. The tip of the stem of the prosthesis should also be able to penetrate into the intact medullary cavity at least 7 cm distally from the old prosthetic bed. In order to ensure equal length of both legs, comparison with the X-ray image of the contralateral hip is necessary. This can lead to a variation in the height of the head of the prosthesis in relation to the greater trochanter.

**Note:** If the Wagner SL Revision Stem is only anchored in the region of the tip of the stem or the zone of anchorage measures less than 7 cm, there is a risk of material fatigue.

## Selection of the Implant Diameter

In addition to stem length, the diameter of the stem of the prosthesis is also determined with the planning template. This is a particularly important part of the preoperative planning process because it is here that most crucial mistakes are made by using stems that are too thin.

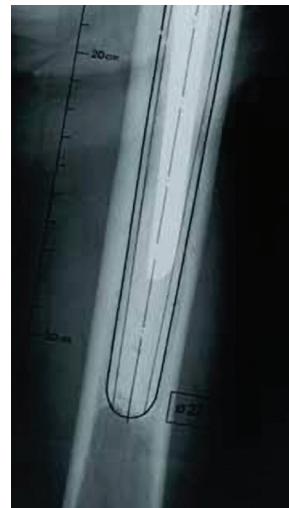The diameter of the stem must be determined in the zone of anchorage, that is, at least 7 cm distally from the zone of the femur that has undergone significant mechanical damage by osteolysis or fracture.

The outline of the planning template corresponds to the contour of the prosthesis. If the correct diameter is chosen, the outline of the prosthesis on the template must overlap the inner contour of the cortical bone by 1 mm on both sides, over a length of at least 7 cm. This extra millimeter takes into account the cutting of the longitudinal ribs into the bone and the small loss of substance due to reaming.

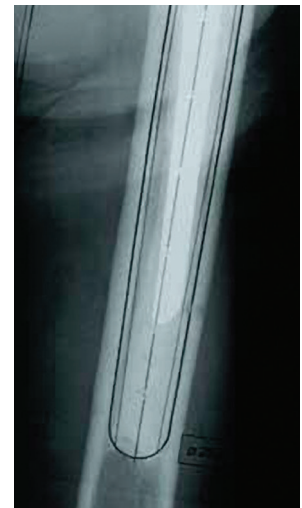The most common mistake made in the preoperative planning, and consequently in the implantation of the prosthesis, is to choose stems that are too thin and too long. If the stem diameter is correct, then anchorage over a length of 7 cm is sufficient.

## Effect of the Bone Quality

In general it is desirable to ream the medullary cavity with the awl until bony resistance is encountered and the marking for the planned center of articulation is level with the tip of the greater trochanter. The depth of anchorage is then checked using the trial prosthesis in order to be able to proceed appropriately by further reaming or use of an implant with a larger diameter. Thanks to the use of trial prostheses, the surgeon can react intraoperatively to variations in bone quality without having to use a number of implants.



Determination of the appropriate stem diameter with the planning template. The contour of the template lies on the contour of the cortical bone. This stem diameter is too small.



With the correct stem diameter, the contour of the template must overlap the contour of the cortical bone by 1 mm.

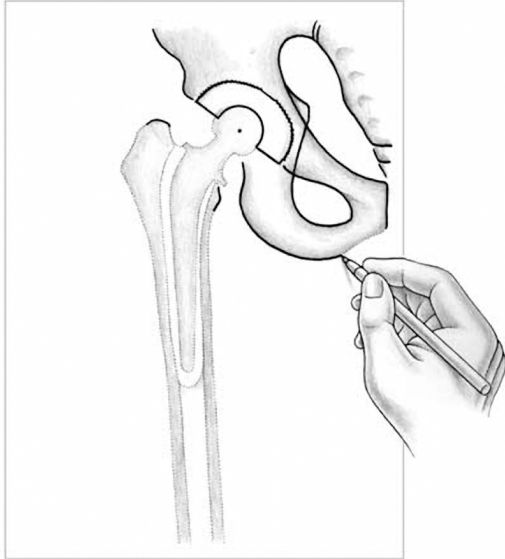


Figure 1

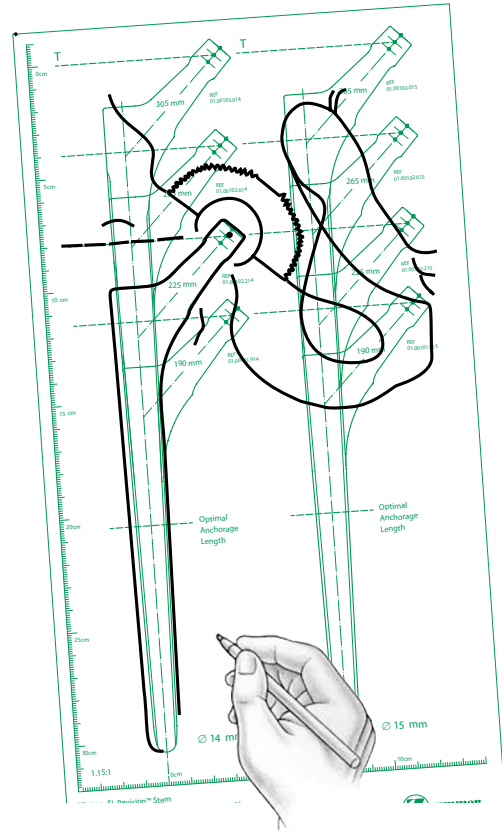


Figure 2

## Drawing the Preoperative Plan

Positioning of the patient and incision after the size of the implant has been determined with the help of the X-ray template and the X-ray images, the planning diagram can be drawn.

First the contour of the iliac bone, including the acetabulum, and the planned acetabular cup are drawn in and the centerpoint of the articulation is marked. In addition, the preoperative position of the femur is drawn in by marking the tip of the greater trochanter (or another reference point) in order to check the intended correction of the length of the leg (Figure 1).

The planning template, with the selected Wagner SL Revision Stem in a physiological slight adduction position, is then placed under this outline drawing so that the center point of the head of the prosthesis on the template lies on top of the previously marked center point of the acetabular implant. The contour of the prosthesis of the template is then transferred onto the outline drawing (Figure 2).



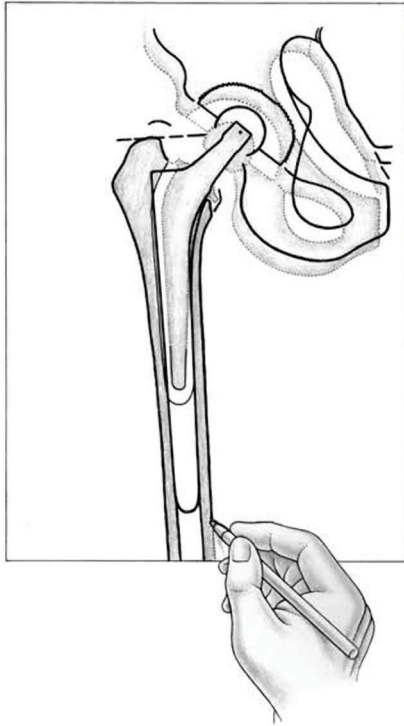


Figure 3

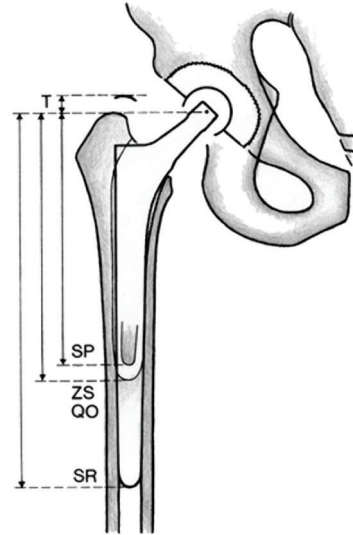


Figure 4

## Drawing the Preoperative Plan (cont.)

This outline drawing is now placed onto the X-ray image. By appropriate adjustment the prosthetic stem can be brought into the center of the medullary cavity. At the tip of the greater trochanter (or another previously selected reference point) the length or the lengthening of the leg can be checked against the preoperative marking (Figure 3). The outer and inner contours of the femur are then drawn in. The tip of the stem of the loosened prosthesis and the distal boundary of the old cement mantle should also be drawn in for the purpose of orientation during the operation.

The sizes of the prostheses and the important length measurements are now entered in this planning drawing: depth of the tip of the stem of the loosened prosthesis (SP), depth of the old cement mantle (ZS), depth of the tip of the stem of the planned Wagner SL Revision Prosthesis (SR) and site of the transverse osteotomy (QO) if a transfemoral approach is planned (Figure 4). The distally limiting transverse osteotomy for the transfemoral approach is generally sited at the distal end of the bone defect. In the case of fractured prosthetic stems or particularly long cement cones, it is often necessary to deviate from this rule. All length measurements are determined according to the scale of the template, which already takes into account the magnification factor of the X-ray image of 115%.

## Reference Points

All these measurements must be made from a reliable reference point that can also be easily located during the operation. The tip of the greater trochanter is almost always used as the reference point, which during the operation can be located and marked with a Steinmann pin.

In the case of very severe bone loss it can happen that the tip of the trochanter cannot be used as reference point. Then other, and if necessary several, reliable reference points have to be selected, for example a prominent bony eminence, cerclage wires or screws on or in the bone or, in particularly severe cases, the epicondylus lateralis femoris or even the lateral knee-joint line.

With the transfemoral approach, the greater trochanter is split longitudinally. In the second phase of the operation, the tip of the trochanter is then no longer suitable as a reference point. Here, the necessary measurements, especially the depth of penetration of the prosthesis, can be taken from the transverse osteotomy, the location of which is exactly defined in the planning drawing.

## Endofemoral Procedure with Posterior Approach

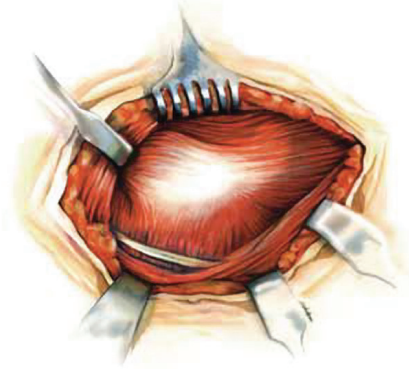


Figure 6

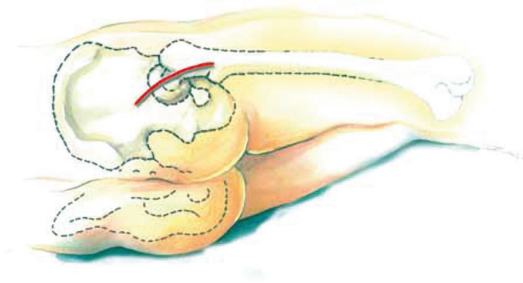


Figure 5

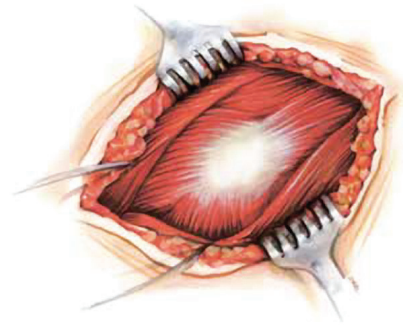


Figure 7

### Step 1

3 cm dorsally from the crista trochanterica and follow the direction of the fibers of the gluteus maximus and the fascia lata (Figure 5).

### Step 2

Split the gluteus maximus and the fascia lata parallel to the direction of the muscle fibers. Spread apart the retracted edges of the gluteus maximus and the fascia lata, exposing the greater trochanter and the short external rotators (Figure 6).

### Step 3

Identify the ischiadic nerve. Resect the adherent scar tissue. Detachment of the tendon of the gluteus maximus is only seldom necessary (Figure 7).

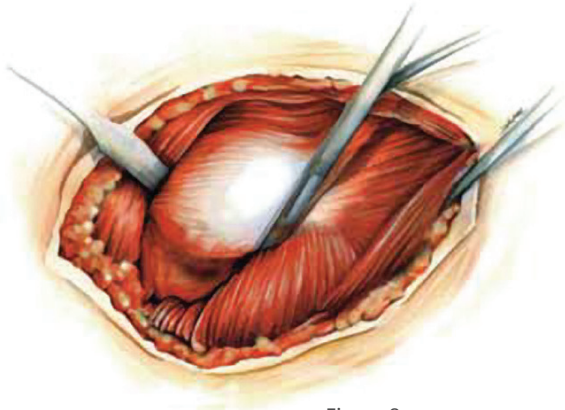


Figure 8

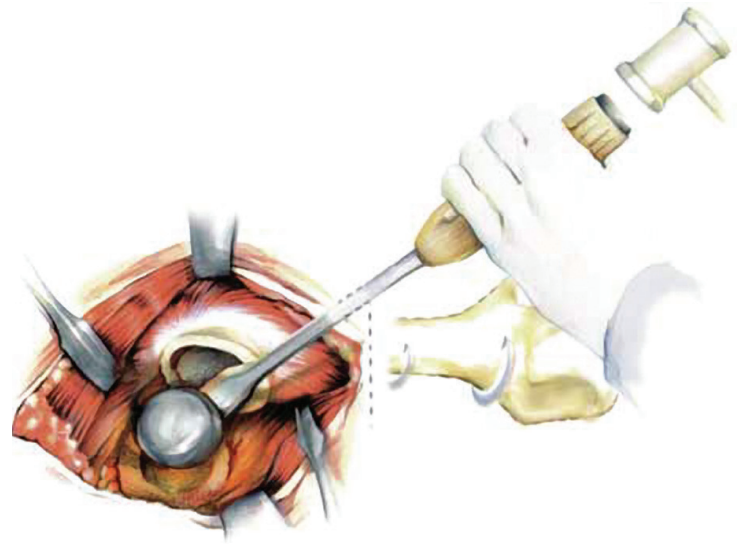


Figure 10

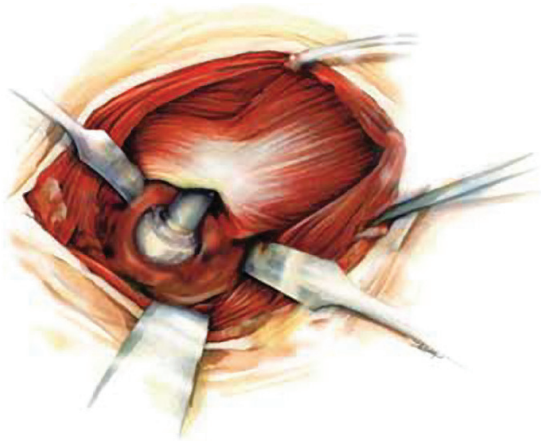


Figure 9

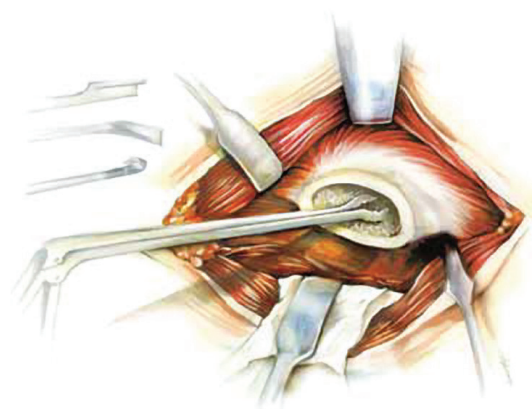


Figure 11

### Step 4

Sever the short external rotators, as well as the piriform muscle, at their tendonous portion at the point of their insertion into the greater trochanter. To facilitate preparation, rotate the leg slightly inward to expose the posterior hip joint capsule.

### Step 5

After the posterior capsule has been exposed, insert one Hohmann retractor under the cranial edge and one under the caudal edge of the neck of the femur and adjust the posterior edge of the acetabulum with a lever (Figure 9).

### Step 6

After the posterior joint capsule has been opened, dislocate the femoral prosthesis dorsally out of the prosthetic cup with the hip flexed and rotated inward. Extract the loosened femoral prosthesis from the medullary cavity (Figure 10).

### Step 7

Break up and completely remove the remaining bone cement from the medullary cavity with the appropriate instruments (Figure 11).



Figure 12

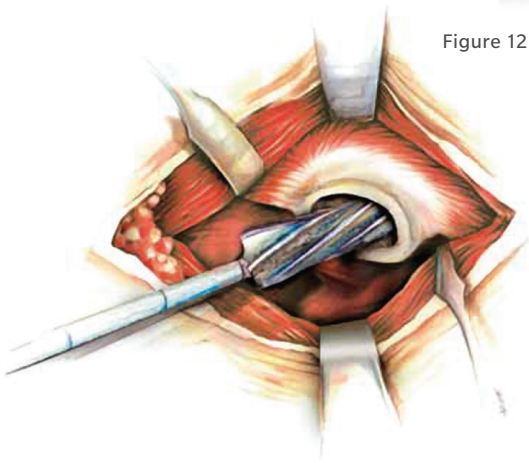
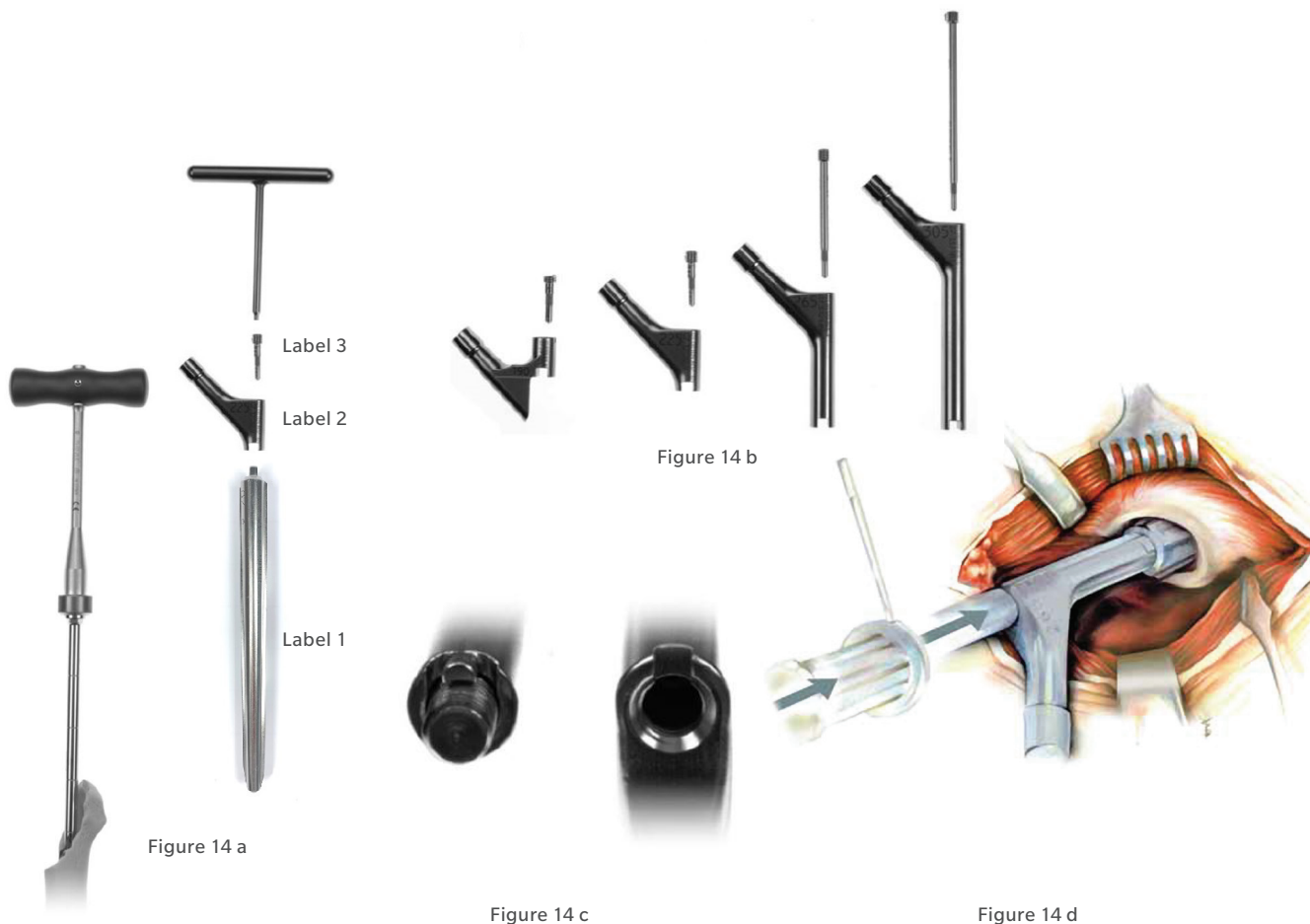


Figure 13

## Step 8

After careful removal of the previous implant and any associated cement, gradually ream the medullary canal of the femur is by attaching the T-handle to the awl, starting with a size that is 4-5mm smaller than the templated size and reaming past the depth of the previous prosthetic bed. There are engraved lines (Figure 12) on the reamer that correspond to the head center of each implant length using a +0mm femoral head. Introduce the awls to a depth where the mark that corresponds to the length of the stem is level with the tip of the greater trochanter (Figure 13). The appropriate stem diameter has been reached when the resistance to reaming is markedly increased. The intended length of the prosthesis is determined during pre-operative planning.

ⓘ **Note:** Reaming can be performed under power (operating at ream speed). However, at a minimum, the final reamer size should be driven manually.



### Step 9

To assess leg length, abductor muscle tension and joint stability, perform a trial range of motion using a trial stem. To assemble the trial prosthesis, three components are used Figure 14a:

- 1) the Distal Stem Trial
- 2) the Proximal Stem Trial that represent the four stem lengths and
- 3) the Proximal Trial Screw used for each respective stem trial length (Figure 14 b).

Based on the final reamer diameter and the length as indicated by the engraved line, assemble the trial stem by placing the appropriate Proximal Trial Screw through the Proximal Stem Trial. Then use the small Hex Wrench to tighten the Proximal Stem Trial onto the Distal Stem Trial.

To insert the assembled trial stem (Figure 14 d), use the Impactor/Extractor by lining up the key on the inserter with the keyed portion of the trial stem (Figure 14 c), and turn the end of the inserter until the threads are fully engaged.

Place the assembled trial stem into the femoral canal, and carefully but firmly seat the trial using moderate strikes of the mallet. If it is difficult to seat the trial stem, there may be a need for additional reaming to remove any impinging bone. Assess the fit again with the trial stem.



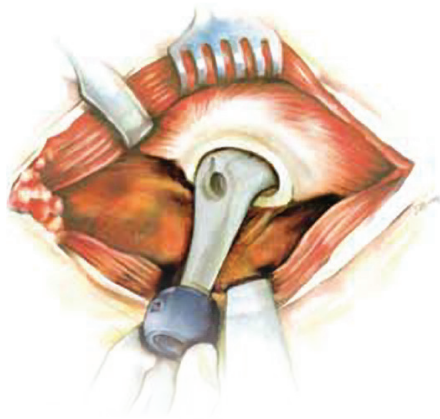


Figure 15

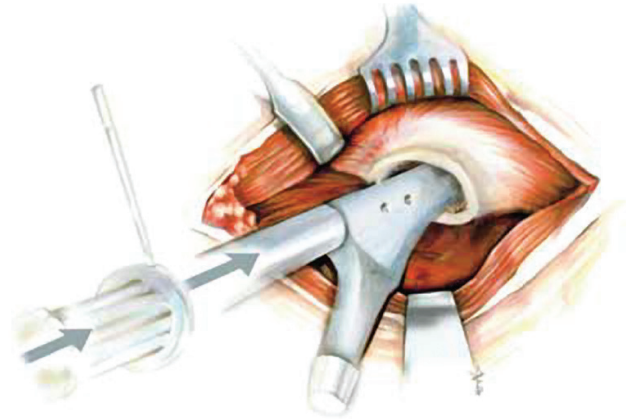


Figure 16

## Step 10

For a trial reduction, Set a trial head with a planned neck length is onto the trial stem (Figure 15). Antetorsion, range of motion and soft tissue tension are checked.

After the test reduction, remove the trial stem from the medullary cavity. If the test reduction did not yield the desired result, preparation must be made to implant a thicker or thinner prosthesis.

## Step 11

For implantation of the prosthesis, screw the impactor/extractor onto the threaded hole at the shoulder of the prosthesis.

**Note:** When screwing the impactor/extractor take care that the positioning pin, at the end of the impactor, is screwed in as far as it will go.

Use the positioning bar to check the antetorsion angle against the lower leg, bent at a right angle.

Place the revision prosthesis in the prepared medullary cavity (Figure 16) and drive it into its definitive position with a few hammer blows. The stability of the anchorage is recognized in the following way: At first the prosthesis penetrates somewhat deeper into the medullary cavity with each hammer blow, until the required stability has been achieved and the prosthesis no longer moves under continued hammer blows. At the same time, the sound of the hammering changes. Usually the elasticity of the bone allows the stem to be driven in by another 2–3 mm after about two minutes waiting time. Finally, check the depth penetration with the tape measure, as determined in the preoperative planning.

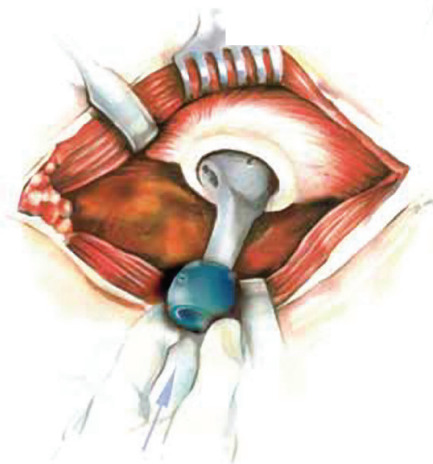


Figure 17

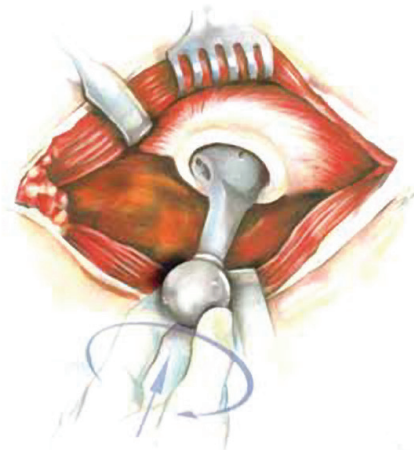


Figure 18

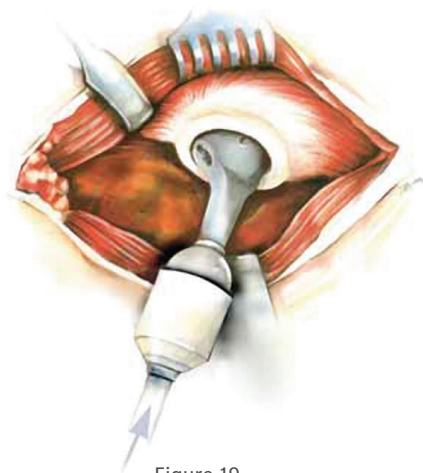


Figure 19

## Step 12

To prepare the final test reduction, set the trial head onto the taper (Figure 17). Check the soft-tissue tension by longitudinal traction on the extended leg: under this traction the prosthetic articulation should only open a few millimeters. It may be the case that a longer prosthetic head must be selected. If the leg has been lengthened considerably, check the tension of the ischiadic nerve.

Fill any remaining cavities between the prosthesis and the surrounding cortical bone of the previous prosthetic bed with bone chips.

## Step 13

After careful cleaning of the taper, mount the definitive head is mounted using a slight rotational movement (Figure 18). Lock the head in place by a light hammer blow on the nylon impactor (Figure 19).

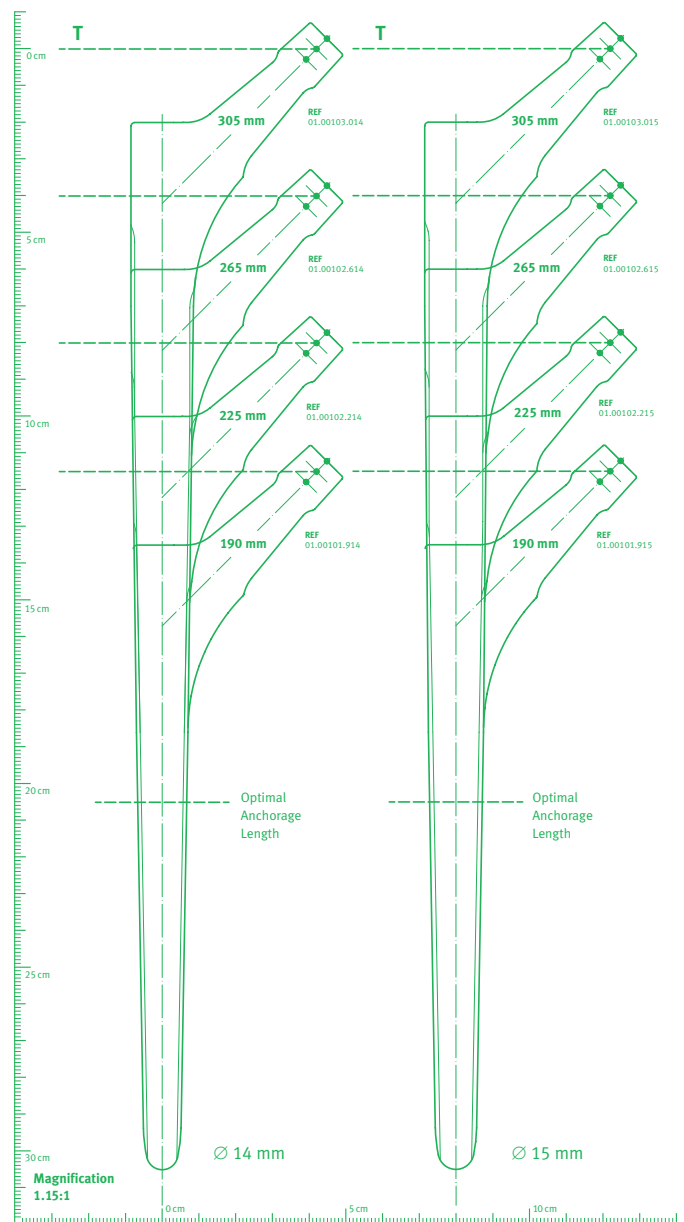


## Transfemoral Approach

After revision of a loosened femoral prosthesis, the loss of bone substance can be so severe that only paper-thin cortical bone remains in the region of the prosthetic bed, often showing defects and fractures. In such grave cases, where the bone of the previous prosthetic bed no longer has any mechanical resistance left, the replacement with the revision prosthesis can be carried out through the transfemoral approach. This procedure simplifies and shortens the operation.

The disadvantage of a long straight stem, more than 225 mm, is that the tip can perforate the ventral cortical bone. Long stems can therefore only be implanted in combination with a transfemoral approach where the antecurvature can be reduced at the point of the transverse osteotomy. This is only of theoretical interest, however, because particularly long stems are only used in cases with very extensive bone damage anyway, for which a transfemoral approach is therefore already indicated.

The intervention requires a precise operative technique and exact preoperative planning. Otherwise there is a risk of serious perioperative complications.



Wagner SL Revision® Stem, Uncemented, Cone 12/14, CCD-Angle 135°

LS No. 06.01.165.0001 – Ed. 2013.02



These reference numbers must correspond to those of the prostheses to be implanted.  
© 2013. All rights reserved. Zimmer GmbH, Subzeralee 8, CH-8604 Wetzlar, Switzerland



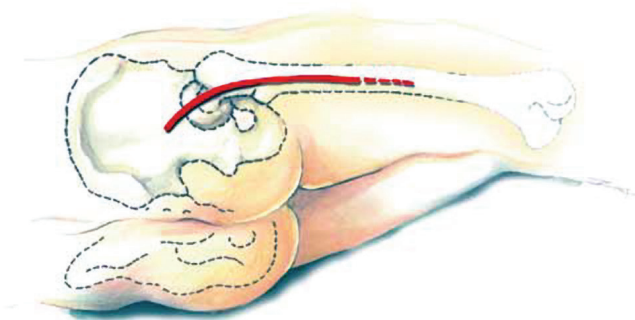


Figure 20

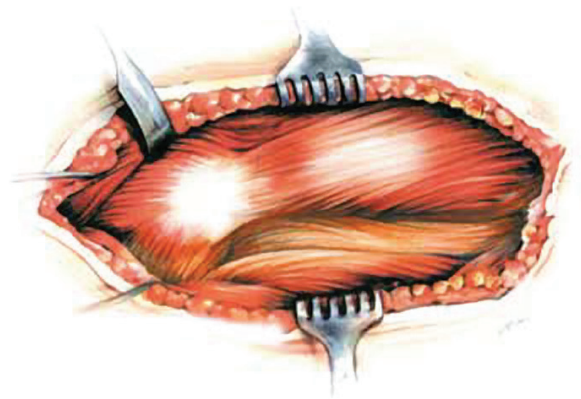


Figure 21

### Step 1

Place the patient in lateral position (Figure 20). The operative approach is a variation of the posterior approach, being lengthened distally. The incision, following the direction of the fibers of the gluteus maximus and the fascia lata, runs three centimeters dorsally from the crista trochanterica toward the lateral femoral epicondyle and ends in the middle third of the thigh.

### Step 2

After the fascia lata and the gluteus maximus have been split parallel to the direction of their fibers, the greater trochanter and the vastus lateralis are exposed (Figure 21).

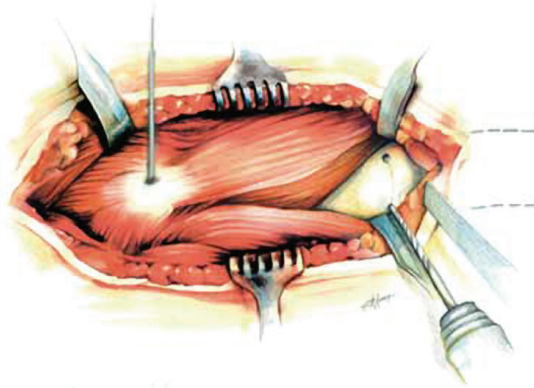


Figure 23

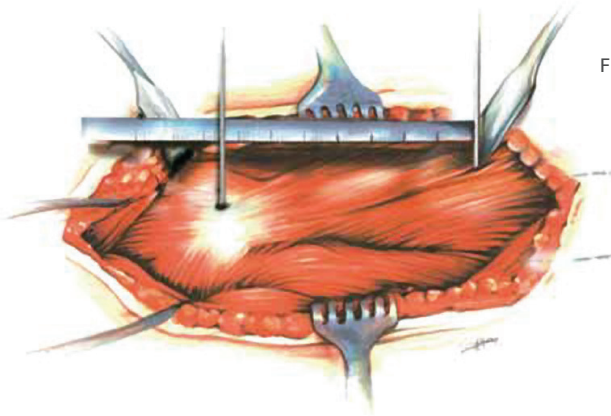


Figure 22

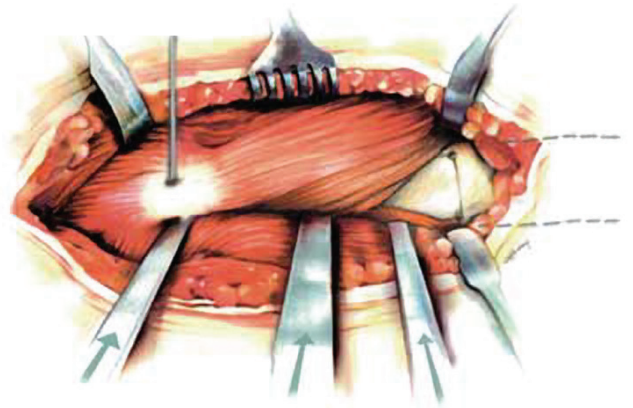


Figure 24

### Step 3

For the opening of the lateral periosteum, in the transfemoral approach, mark the level for the semicircular or complete transverse osteotomy, determined during preoperative planning. This distance corresponds to the length of the previous prosthetic bed. Set a Steinmann pin on the tip of the greater trochanter (Figure 22). Measure the distance for the osteotomy this point and mark it with a distal Steinmann pin.

### Step 4

Semicircular or complete transverse osteotomy for the distal boundary of the transfemoral approach. Complete transverse osteotomy also starts with a semicircular osteotomy and is completed, after removal of the prosthesis, with the oscillating saw (Figure 23).

To establish the bone flap, create a dorsal and a ventral drill hole. Carefully separate the cortical bone between the two drill holes with a sharp-bladed chisel or oscillating saw. The distance between the two drill holes determines the width of the bone flap.

### Step 5

Set the dorsal boundary of the bone flap by splitting the cortical bone from the semicircular transverse osteotomy along the linea aspera. In the proximal direction, run the osteotomy through the middle of the greater trochanter (Figure 24). Likewise, split the insertion of the gluteus medius over a distance of approximately 3 cm.

ⓘ **Note:** The tendon of origin of the vastus lateralis should be treated with care because it absorbs the tensile force of the gluteus medius and prevents the greater trochanter from rising.

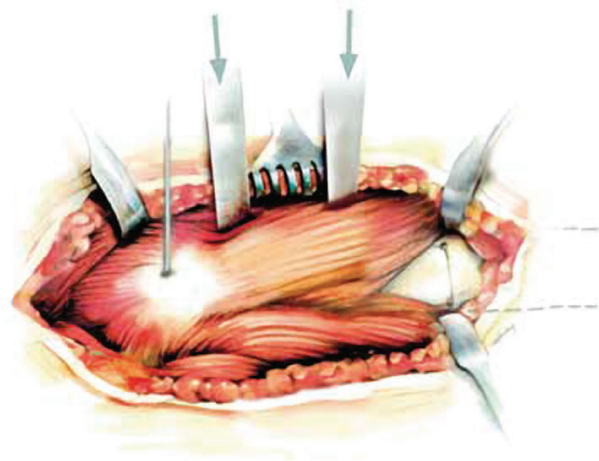


Figure 25

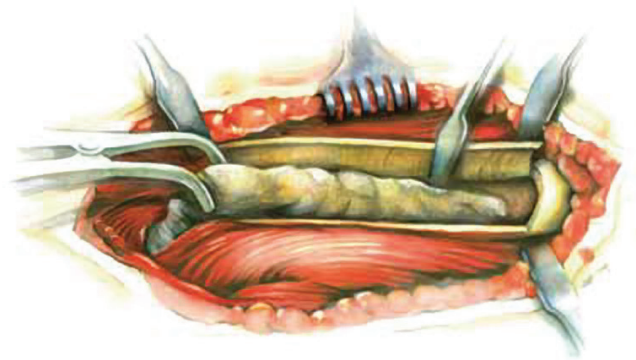


Figure 26

## Step 6

To establish the ventral boundary of the bone flap, place a row of small stab osteotomies along the boundary line in continuation of the ventral drill hole in the proximal direction. Bluntly introduce a narrow straight chisel between the fibers of the vastus lateralis until it reaches the surface of the bone (Figure 25). At this point, twist the chisel toward the boundary line and separate the thin cortical bone. This procedure is repeated a number of times along the boundary line. In this way the muscles will not be detached from the surface of the bone, so that the blood supply of the bone flap is preserved.

ⓘ **Note:** In the case of very thin and flexible cortical bone, the bone flap can first be lifted slightly and the stab osteotomies marking the boundary can be made beneath the flap through the medullary cavity.

## Step 7

Introduce bone spreaders into the dorsal osteotomy fissure and cautiously lift the bone flap. When the cortical bone breaks at the ventral row of stab osteotomies the flap can then be completely opened. However, the connection to its muscular covering should remain intact. After the flap has been opened and the cicatricial tissue on the neck of the prosthesis has been resected, the loosened femoral prosthesis will be accessible along its entire length, together with the attached cement. It can now be easily removed from the femur (Figure 26).

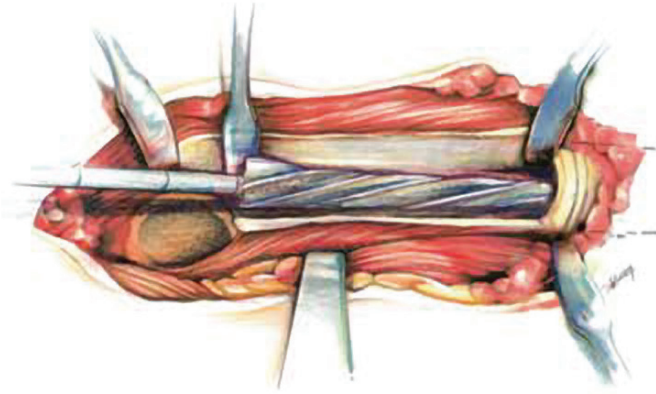


Figure 28

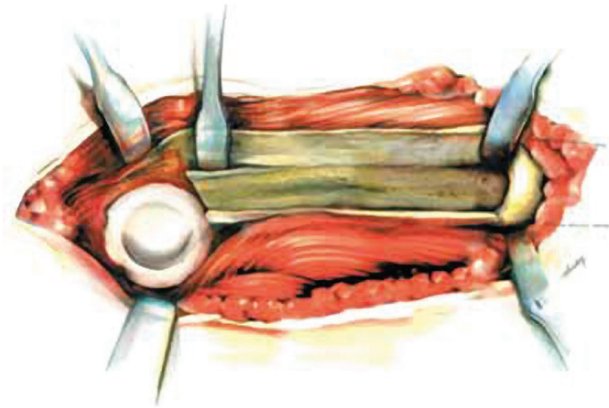


Figure 27

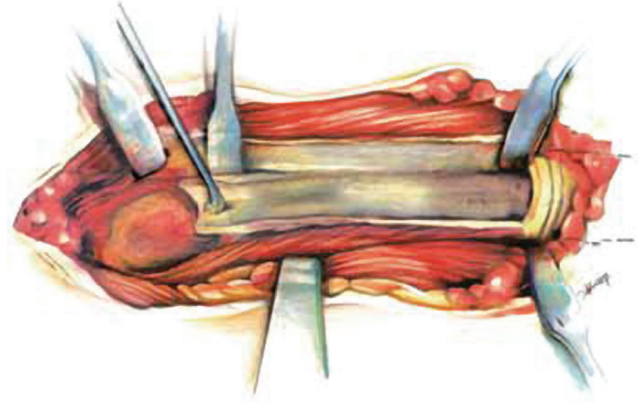


Figure 29

## Step 8

After removal of the loosened femoral prosthesis, the prosthetic cup will also be readily accessible (Figure 27). If necessary, it can be replaced transfemorally. The femoral stem can be secured against breaking with a double cerclage of steel wire of 1.5 mm diameter. The need for cerclage depends on the strength of the bone. In case of doubt, a cerclage should always be applied, with great care being taken to ensure that the wire does not touch the stem of the prosthesis.

## Step 9

The femoral medullary cavity is conically widened with the awls distal from the original prosthetic bed (Figure 28).

- ⓘ **Note:** Reaming can be performed under power (operating at ream speed). However, at a minimum, the final reamer size should be driven manually.
- ⓘ **Note:** For more detail on canal preparation please refer to Step 8 of **Endofemoral Procedure with Posterior Approach**.

## Step 10

Mechanically clean the internal surface of the bony shell surrounding the original prosthetic bed with great care, until spots of blood appear everywhere (Figure 29).



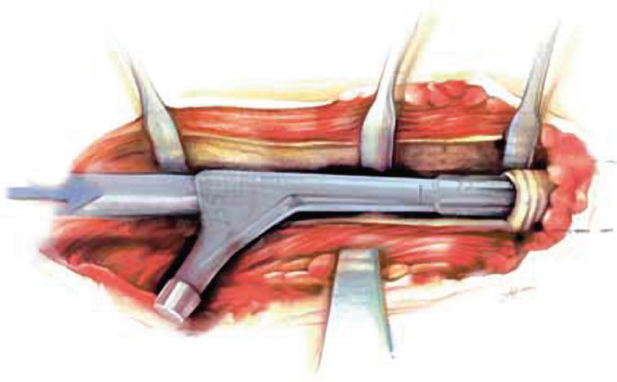


Figure 30

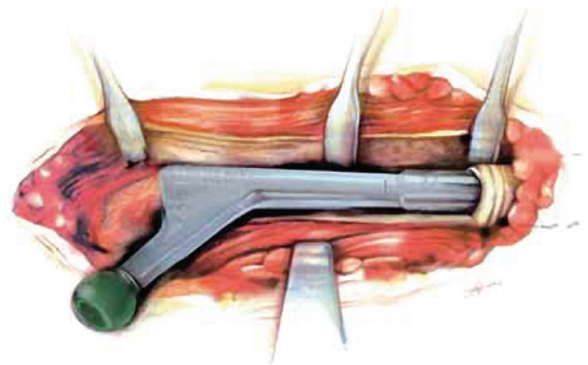


Figure 31

### Step 11

Use the modular trial prostheses to check the depth and positioning of the prosthesis. Insert the trial prosthesis, corresponding to the prosthesis size defined in the preoperative plan and the diameter of the last awl used, into the medullary canal. Drive the trial prosthesis into the final positioning with the impactor/extractor (Figure 30).

ⓘ **Note:** For more detail on provisional assembly and insertion, please refer to Step 9 of **Endofemoral Procedure with Posterior Approach**.

### Step 12

For a trial reduction, set a trial head with a planned neck length is set onto the trial stem (Figure 31). Check antetorsion, range of motion and soft tissue tension. After the test reduction, remove the trial stem from the medullary cavity. If the test reduction did not yield the desired result, preparation must be made for implanting a thicker or thinner prosthesis.

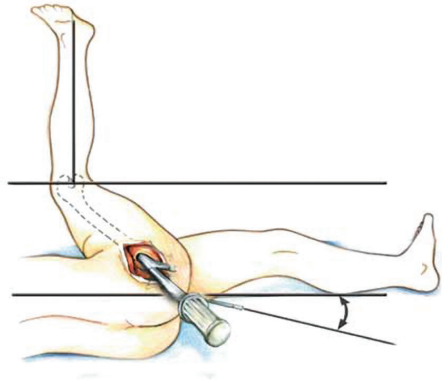


Figure 33

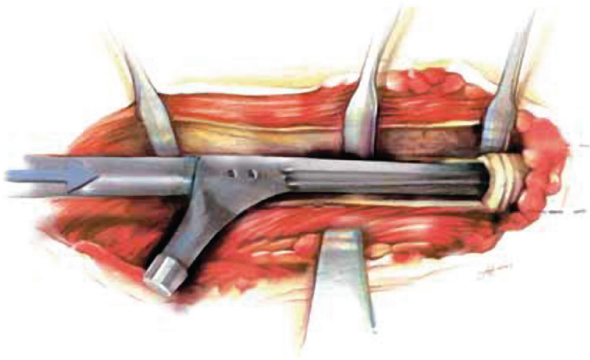


Figure 32

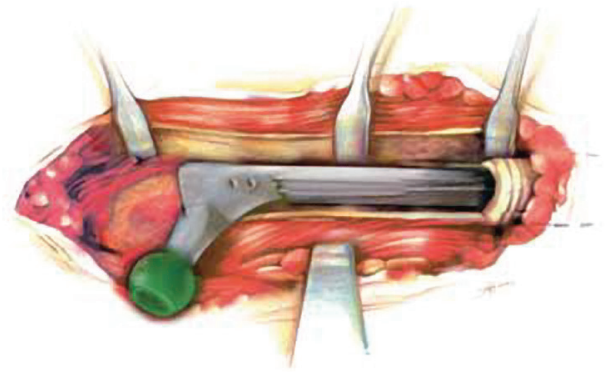


Figure 34

### Step 13

For the placement of the prosthesis, screw the impactor/extractor onto the threaded hole at the shoulder of the prosthesis. In screwing it on, care must be taken that the positioning pin at the end of the impactor is screwed in as far as it will go. The positioning pin on the impactor handle permits optimal setting of antetorsion.

Implant the Wagner SL Revision Prosthesis in the prepared medullary cavity (Figure 32) of the femur and drive it into its definitive position with a few hammer blows. The stability of the anchorage is recognized in the following way: By referring to the transverse osteotomy (or some other point of reference), it is possible to see how the prosthesis penetrates somewhat further into the bone (Figure 33) with each blow of the hammer until, with continued hammer blows of the same intensity, the prosthesis no longer moves relative to the bone. In this phase, the sound of the hammering changes.

Usually the elasticity of the bone allows the stem to be driven in by another 2–3 mm after about 2 minutes waiting time. Finally the depth of penetration is checked with the tape measure, as determined in the preoperative planning.

### Step 14

To prepare the test reduction, set a trial head onto the taper (Figure 34). In the test reduction, check the the stable joint closure of the prosthesis in inward rotation and flexion. Evaluate soft-tissue tension by longitudinal traction on the extended leg: under this traction the prosthetic articulation should only open a few millimeters. It may be the case that a longer prosthetic head must be selected. If the leg has been lengthened considerably, check the tension of the ischiadic nerve.

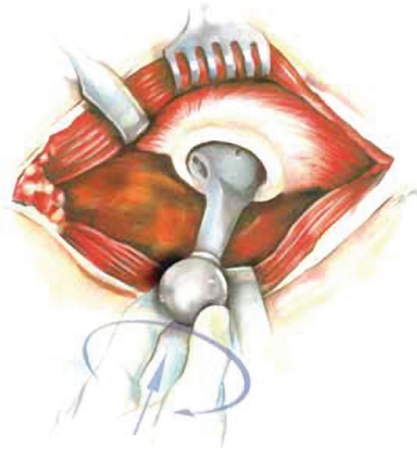


Figure 35

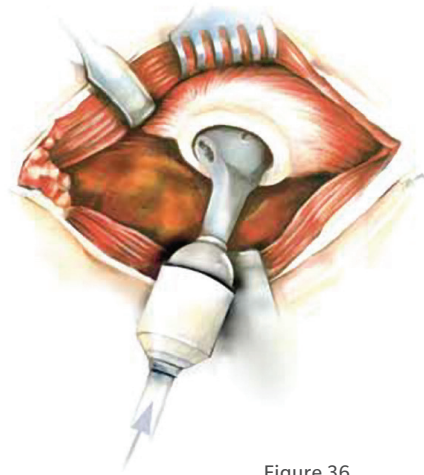


Figure 36

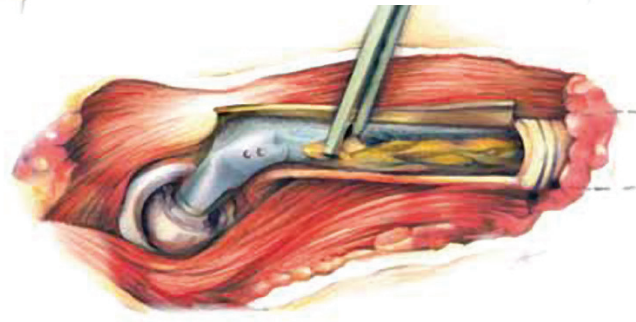


Figure 37

## Step 15

After careful cleaning of the taper, mount the definitive head using a slight rotational movement (Figure 35). Lock the head in place by a light hammer blow on the nylon impactor (Figure 36). Reduce the prosthesis.

⊖ **Note:** After reduction, the bone flap of the transfemoral approach often has the tendency to remain on the anterior surface of the prosthesis and must be reduced onto the lateral surface. A diastasis at the level of the transverse osteotomy must be avoided. It may be necessary to fix the bone flap in the reduced position with a strong suture or with a cerclage. Care must be taken that the wire does not touch the prosthesis. No metal cerclage wires may be fixed through the drill holes in the proximal region of the prosthesis, since these can lead to the production of undesirable metal abrasion particles or entail the risk of corrosion of the implants.

⊖ **Note:** If bone defects remain on the lateral surface of the femur, these should be filled with bone chips. Bone defects on the medial surface of the femur do not require special attention because here, the spontaneous ossification is rapid.

Finally, the two parts of the greater trochanter are adapted and, like the longitudinally separated tendon of the gluteus medius, firmly sutured. Because of the longitudinal separation of these structures in the direction of the tensile forces, the healing here is without problems. After insertion of suction drainage the fascia lata, as an important traction structure, is closed with purse-string sutures.



## **Postoperative Treatment**

The Wagner SL Revision Stem, firmly anchored in stable bone, permits immediate full weight bearing. With extensive reconstruction of the acetabulum, the surgeon must decide how soon the patient may bear full weight on the leg. In general, it will be possible to mobilize the patient on the first or second postoperative day. Until the incision has healed and neuromuscular coordination has been regained, the use of crutches is advisable. In the case of very complex reconstructions and poor bone condition, the surgeon must establish an individual aftercare program.





All content herein is protected by copyright, trademarks and other intellectual property rights, as applicable, owned by or licensed to Zimmer Biomet or its affiliates unless otherwise indicated, and must not be redistributed, duplicated or disclosed, in whole or in part, without the express written consent of Zimmer Biomet.

This material is intended for health care professionals. Distribution to any other recipient is prohibited.

For indications, contraindications, warnings, precautions, potential adverse effects and patient counselling information, see the package insert or contact your local representative; visit [www.zimmerbiomet.com](http://www.zimmerbiomet.com) for additional product information.

Not intended for surgeons practicing medicine in France. Check for country product clearances and reference product specific instructions for use.

Zimmer Biomet does not practice medicine. This technique was developed in conjunction with health care professionals. This document is intended for surgeons and is not intended for laypersons. Animations and virtual reality are provided as a visual guide based on surgical techniques; a written copy of the surgical technique is available at [www.zimmerbiomet.com](http://www.zimmerbiomet.com) or from your local representative. Each surgeon should exercise his or her own independent judgment in the diagnosis and treatment of an individual patient, and this information does not purport to replace the comprehensive training surgeons have received. As with all surgical procedures, the technique used in each case will depend on the surgeon's medical judgment as the best treatment for each patient. Results will vary based on health, weight, activity and other variables. Not all patients are candidates for this product and/or procedure. Caution: Federal (USA) law restricts this device to sale by or on the order of a surgeon. Rx only.

© 2019 Zimmer Biomet

**For Ordering Information, please refer to 0467.X-GLBL-en Wagner SL Revision Hip Stem-Ordering Information.**



2810.1-GLBL-en REV1119

 **Legal Manufacturer**  
Zimmer GmbH  
Sulzerallee 8  
8404 Winterthur, Switzerland  
Telephone +41/(0)52 262 60 70  
Fax +41/(0)52 262 01 39

[www.zimmerbiomet.com](http://www.zimmerbiomet.com)

 **2797**

CE mark on a surgical technique is not valid unless there is a CE mark on the product label.